

# Platelet-Rich Fibrin Matrix (PRFM) for Androgenetic Alopecia

Anthony P. Sclafani, MD, FACS<sup>1,2</sup>

<sup>1</sup>Division of Facial Plastic Surgery, New York Eye and Ear Infirmary of Mt. Sinai, New York, New York

<sup>2</sup>Department of Otolaryngology, Icahn School of Medicine at Mt. Sinai, New York, New York

Address for correspondence: Anthony P. Sclafani, MD, FACS, Division of Facial Plastic Surgery, New York Eye and Ear Infirmary of Mt. Sinai, New York, NY 10003 (e-mail: asclafani@nyee.edu).

Facial Plast Surg 2014;30:219–224.

## Abstract

The objective of this study was to determine the effect of platelet-rich fibrin matrix (PRFM) treatment on androgenetic alopecia. Prospective cohort study of 15 (9 male and 6 female) subjects with androgenetic alopecia for at least 1 year who were treated with intradermal injections of autologous PRFM three times on a monthly basis. Hair density indices were measured in triplicate in the same area of the scalp before the treatment and 1, 2, 3 and 6 months after initial treatment. Hair density index (HDI) measurements were obtained and compared with pretreatment values for each subject. After a series of three intradermal PRFM injections, hair density indices increased significantly at 2 ( $47.4 \pm 22.7\%$ ,  $p = 0.0031$ ) and 3 ( $106.4 \pm 56.9\%$ ,  $p = 0.0277$ , paired t-test) months after the initial treatment, and approached statistical significance at 6 months ( $75.1 \pm 46.82\%$ ,  $p = 0.0606$ ) after the initial treatment. Patients who achieved greater than 25% increase in HDI by 2 months after the initial treatment were more likely to have greater than 25% improvement at 6 months after the initial treatment (100 vs. 16.7%,  $p = 0.0476$ ). Androgenetic alopecia affects a significant number of both men and women. A series of intradermal injections of autologous PRFM increased the HDI in patients with androgenetic alopecia at 2 and 3 months after initial treatment; this improvement approached statistical significance at 6 months after initiating treatment. Autologous PRFM injections may be a valuable treatment for androgenetic alopecia, particularly in cases with mild hair loss. The level of evidence is level 2.

## Keywords

- ▶ platelet-rich fibrin matrix
- ▶ platelet-rich plasma
- ▶ growth factors
- ▶ alopecia
- ▶ hair restoration

Androgenetic alopecia affects up to 30% of men over the age of 30, greater than 50% of men over 50 and can also affect women.<sup>1</sup> Several thousand products have been promoted for hair regrowth. Only two medications, minoxidil and finasteride, and low level 655 nm laser devices are Food and Drug Administration (FDA) approved for the treatment of hair loss. Minoxidil is a peripheral vasodilator, but has also been shown to directly increase the proliferation of dermal papilla cells, presumably through ERK and Akt phosphorylation, increased Bcl-2 expression and decreased Bax expression. Minoxidil may promote enhanced dermal vascularity (known to be associated with anagen phase<sup>2,3</sup> as well as have direct mito-

genic and antiapoptotic effects).<sup>4</sup> Finasteride, which blocks 5 $\alpha$ -reductase, reduces levels of dihydrotestosterone, and prolongs anagen, leading to increased hair counts and thickening of miniaturized hairs.<sup>5,6</sup> Dutasteride, another 4-aza steroid, is approved for the use in benign prostatic hypertrophy and more effectively blocks all isoforms of 5 $\alpha$ -reductase but is not FDA approved for hair loss treatment.<sup>1</sup>

In general, hair loss treatments can be directed toward induction of anagen, prolongation of anagen, or inhibition of exogen. Follicles in anagen are highly vascularized; this vascularity regresses during catagen. Dermal papilla cells have been shown to express and bind vascular epithelial

Issue Theme 11th International Symposium of Facial Plastic Surgery; Guest Editors, Jonathan M. Sykes, MD, FACS, and Anthony P. Sclafani, MD, FACS.

Copyright © 2014 by Thieme Medical Publishers, Inc., 333 Seventh Avenue, New York, NY 10001, USA. Tel: +1(212) 584-4662.

DOI <http://dx.doi.org/10.1055/s-0034-1371896>. ISSN 0736-6825.

growth factor (VEGF). It has been suggested that exogenous VEGF may enhance anagen.<sup>3</sup> More broadly, treatment with growth factors and platelet concentrates has been used to stimulate hair growth. Zimber et al noted increased hair thickness and terminal hair density up to 1 year after intradermal injections of a proprietary releasate from neonatal fibroblasts grown under hypoxic conditions (known to induce several cytokines, including VEGF, fibroblast growth factor [FGF], keratinocyte growth factor [KGF], and Wnt 7a).<sup>7</sup> Uebel et al treated hair grafts with platelet-rich fibrin matrix (PRP) before placement and noted a 15% increase in hair density over control areas.<sup>8</sup> Rastegar et al reported enhanced dermal papilla cell growth in culture when treated with an herbal extract in the presence of platelet rich plasma, and noted increased phosphorylation of ERK and Akt in these cells after PRP treatment.<sup>9</sup> Patients who were injected subcutaneously over a 9-week period with particles of low-molecular-weight heparin/protamine coincubated with PRP showed increased hair thickness and higher hair counts at 12 weeks; the microparticles were felt to bind the growth factors and prolong exposure time.<sup>10</sup> Li et al injected mice every 3rd day with PRP for 3 weeks and noted increased hair regrowth.<sup>11</sup>


This study was designed to evaluate the effect of platelet-rich fibrin matrix (PRFM) on balding scalp. PRFM presents viable, intact platelets in a fibrin matrix, which produces a more prolonged exposure to growth factors in a more natural time course. It is believed that these more natural kinetics will yield more sustained hair growth.

## Methods

In this study, 15 patients with mild to moderately severe hair loss were included. Hair loss was long-standing in all patients and ongoing in most, and all patients under the age of 40 had previously undergone dermatologic evaluation and had been diagnosed with androgenetic alopecia.

**Assessment:** At the initial and all subsequent (1, 2, 3, and 6 months after initial treatment) visits, a hair density index (HDI) was obtained from within the area of the subject's primary concern. Briefly, a 2 cm × 2 cm square in the midline at a set distance posterior from the soft tissue nasion was identified and marked. Hair was parted and taped to expose only the hair contained within this square. The HDI was then measured using a validated, proprietary device (Hair Check, Divi International Co., Miami, FL; –Fig. 1).<sup>12</sup> Measurements were made in triplicate, as close to the scalp as possible, and the same area was assessed at each visit.

**Preparation of PRFM:** A total of 18 mL of peripheral blood was collected using a 19-gauge needle into specialized vacuum tubes containing a proprietary, thixotropic separator gel (Selphyl, Aesthetic Factors, Inc., Wayne, NJ) and centrifuged at 1,100 g for 6 minutes. This typically produced 8 to 9 mL of platelet-containing plasma (isolated from red and white blood cells, with an approximately 80% platelet yield). This platelet/plasma mix was then transferred via a closed system into a second vacuum tube containing CaCl<sub>2</sub>, which activated the fibrin polymerization process; the suspension was in-



**Fig. 1** Assessment of hair density index (HDI). (A) Hair from a 2-cm square of interest is isolated and advanced into the reading slot of the device. (B) The cross-sectional "bulk" of hair is assessed as the instrument is closed around the hair. Measurement is taken close to the skin, assuring assessment of HDI no greater than 1.5 cm from the scalp (recent hair growth).

jected within 8 to 10 minutes of activation before a solid fibrin mesh with adherent platelets develops.

**Treatment:** Aliquots (0.1 mL) of activated PRFM suspension were injected intradermally into areas of thinning hair/bald scalp separated by 5 to 8 mm. Subjects were treated every 4 weeks for three treatment sessions.

**Analysis:** All data were entered into a digital spreadsheet (Excel 2010, Microsoft Corp., Redmond, WA) and analyzed with statistical software (GraphPad Prism version 6.0b for Mac OS X, GraphPad Software, La Jolla, CA, www.graphpad.com). Hair density indices were converted into percent of pretreatment value for each subject and analyzed by two-tailed paired *t*-test and chi-square analysis, with a *p* value of ≤ 0.05 set for statistical significance.

This study was approved by the Institutional Review Board of The New York Eye and Ear Infirmary, NY and was listed on clinicaltrials.gov (NCT01590238).

## Results

A total of 15 subjects were enrolled and treated. All subjects received all three treatments, but two patients failed to

follow-up after the third treatment and were unreachable by telephone. These were excluded from analysis. The average age of subjects was  $43.2 \pm 18.2$  years. Of the seven men treated, three were Norwood class 3, one was Norwood class 4, one was Norwood class 5, and two Norwood class 6. Six women were treated: five were Ludwig class 2 and one was Ludwig class 1. Seven patients used minoxidil (four active and three previously) and four used finasteride (two active and two previously); five patients were never treated pharmacologically.

All 13 remaining subjects requested treatment of the frontal area; 9 also requested treatment of the crown, while 5 were additionally treated in the occipital area and 2 were treated in the temples. The average volume injected during treatment was  $6.68 \pm 1.60$  mL. Nine patients completed the 3-month follow-up (1 month after the third treatment) visit; the same nine patients also completed the 6-month follow-up visit (4 months after the last treatment).

There was a wide range of hair density scores recorded from patients, and results are expressed as a percentage of the initial (pretreatment) value. The mean percentage of initial value at the 1-month visit was  $125.2 \pm 17.39$  (SEM); at the 2-month visit, the score was  $147.4 \pm 22.71$ ; at the 3-month visit, the score was  $206.4 \pm 56.89$ ; and at the 6-month visit, the score was  $175.1 \pm 46.82$ . The 2- and 3-month follow-up visit values were statistically higher than pretreatment ( $p = 0.0031$  and  $p = 0.0277$ , respectively, paired *t*-test). The value at the 6-month visit approached significance ( $p = 0.0606$ ) (Fig. 2).

Subjectively, patients with more modest degrees of hair loss (Fig. 3) were more likely to notice improvement, as patients with Norwood classification 5 or 6 (Fig. 4) did not note significant improvements, even in cases of significant (74% increase in HDI) improvement. Conversely, patients with Norwood 3 classification noted subjective aesthetic improvement in cases with as little as 4 to 7% improvement from baseline, frequently commenting their scalp was "less noticeable," and less hair styling was necessary to camouflage hair loss.

All patients tolerated the procedures well. Of the 13 patients for whom follow-up was available, no patients developed any noticeable ecchymosis. No patients noted any significantly worsened hair shedding or developed infections, nodules, or cysts.

## Discussion

Normal hair density is 300 to 400 hairs/cm<sup>2</sup>, and a 25% loss is noted as hair loss.<sup>13</sup> Hair loss is a significant problem worldwide, and can be attributed to nutritional deficiency, infectious, autoimmune, or genetic causes, among others. Idiopathic alopecia is common, and when severe may be treated with topical or oral medications or with hair replacement surgery. Over 100,000 hair restoration procedures were performed in the United States in 2010, with almost 300,000 performed worldwide.<sup>14</sup> Topical minoxidil (over \$60 million in annual sales) changes potassium channel kinetics as well as increases local production of prostaglandin (PG) E<sub>2</sub>.<sup>15</sup> Med-

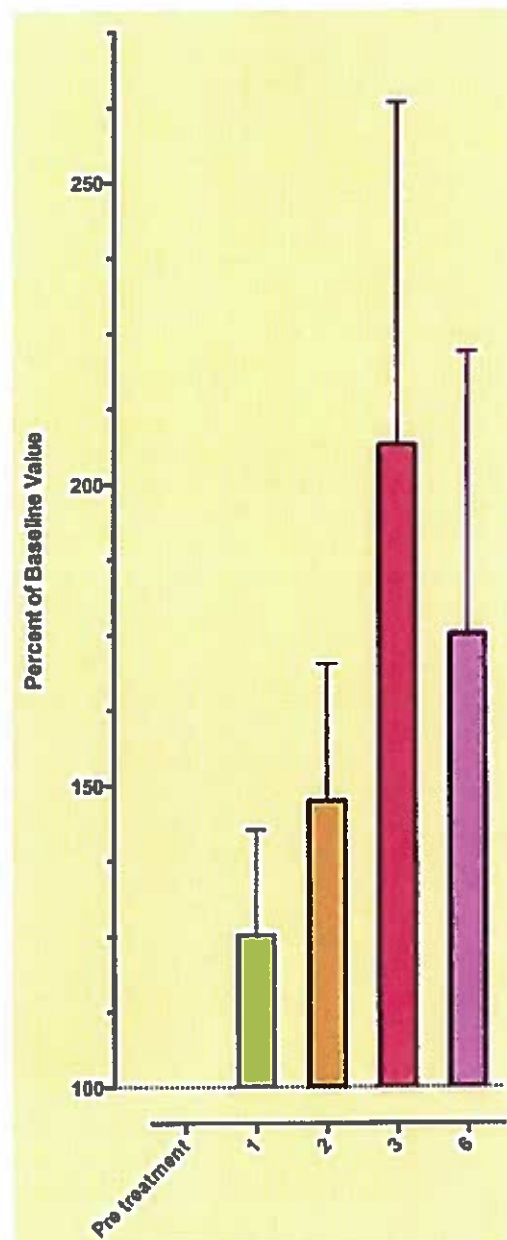
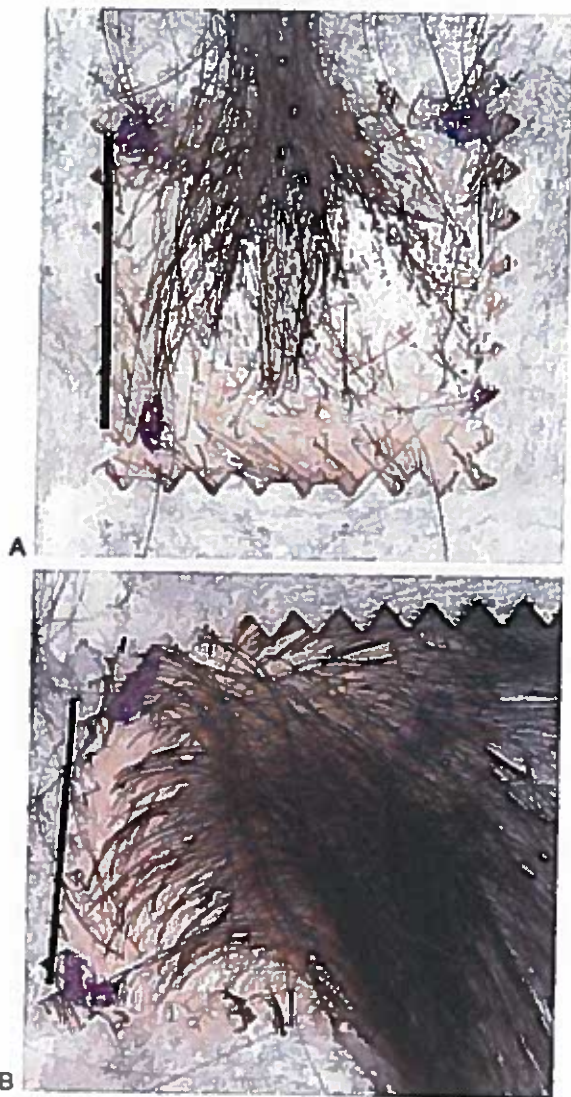


Fig. 2 Effect of platelet-rich fibrin matrix treatment on hair density. Results expressed as a percentage of baseline hair density index and plotted as a function of months after initial treatment.

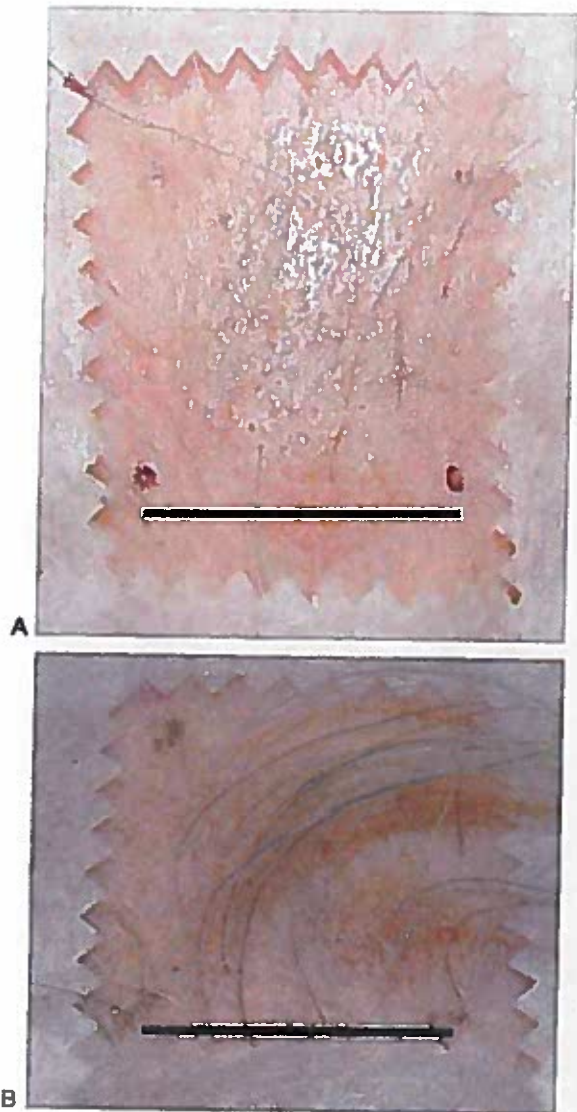
ications such as finasteride (\$424 million in sales in 2012) and dutasteride inhibit the activity of isoforms of 5 $\alpha$  reductase and block the conversion of testosterone to dihydrotestosterone, but may have significant side effects. Microfollicular hair transplantation (\$1.9 billion worldwide in 2010), even when expertly performed, is limited by the degree of alopecia and the remaining reservoir of donor follicles; in addition, there is considerable expense and morbidity associated with such surgery.

Because the etiologies of hair loss are so diverse, a precise understanding of hair follicle physiology is essential but only now being clearly elucidated. Stem cells located in the hair





**Fig. 3** (A) Pre- and (B) Posttreatment. Treated scalp shows significant improvement, expressed as a 63% increase in hair density index compared with pretreatment. Blue dots indicate corners of 2 × 2 cm square; bar: 2 cm.



**Fig. 4** (A) Pre- and (B) 6 months postinital treatment with platelet-rich fibrin matrix. Significant improvement in hair follicle density and hair shaft thickness is obvious (74% increase in hair density index). This subject, however, did not consider the change satisfactory.

follicle bulge, at the outer root sheath below the insertion of the arrector pill muscle, interact with dermal papilla cells and differentiate into matrix keratinocytes. These cells migrate downward and push the papilla downward during early anagen.<sup>16,17</sup> As the dermal papilla moves downward into subcutaneous fat, bulge stem cell activity decreases as these cells become quiescent.<sup>16</sup> Hair growth occurs as the matrix cells differentiate into cells of the medulla, cortex, and cuticle,<sup>16</sup> but since these transient amplifying cells of the matrix have a finite replicative capacity, they will eventually undergo terminal differentiation; anagen thus has a defined lifetime, generally lasting 2 to 5 years. Catagen then follows, lasting a few days to a few weeks. During this phase, the dermal papilla regresses upward into the dermis, ultimately resting close to the bulge at the beginning of telogen.<sup>18</sup> After a telogen phase

lasting, on average, about 3 months and shedding of the hair (exogen phase), anagen ensues with bulge cell proliferation and migration to the base of the hair follicle.<sup>18</sup>

Androgenetic alopecia is characterized by the genetically determined gradual loss and miniaturization of the normally thick hair follicles. The length of anagen, and the length and thickness of hair is also shortened in anagen. Increased numbers of lymphocytes and mast cells are seen around miniaturizing follicles, especially in the bulge region<sup>15</sup>; this is in contrast to alopecia areata, in which inflammatory cells localize to the bulb, leaving the bulge intact for later hair regrowth.<sup>19</sup> Increased expression of PGD2 synthase and increased levels of PGD2 are seen in balding scalp. Interestingly, while the number of bulge stem cells does not seem to change follicles in balding scalp, there is a noticeable decrease

in the number of transient amplifying cells derived from these stem cells, suggesting a blocked pathway, either by a lack of a stimulator or the presence of an inhibitor.<sup>15</sup>

Stimulatory signals to bulge cells may include platelet-derived growth factor (PDGF)<sup>20</sup> (possibly from immature intradermal adipocytes<sup>21</sup>) Wnt 7a, VEGF, FGF, KGF, and follistatin,<sup>7</sup> while FGF-7 has been shown to act on the dermal papilla cells to prolong anagen,<sup>11</sup> PGD2 and PGJ2 have been shown to promote the onset of catagen, with decreased hair lengthening, follicular miniaturization, and progression to telogen.<sup>15</sup> During later stages of anagen, mature intradermal adipocytes increase production of bone morphogenetic protein (BMP)-2, which inhibits bulge cell activity.<sup>7,21</sup>

Attempts to modulate the microenvironment of the senescent hair follicle with growth factors has been surprisingly anecdotal, with few well-performed clinical trials. Uebel et al soaked hair grafts with activated PRP (aPRP) for at least 15 minutes before placement and noted a 15% increase in hair density over control grafted areas.<sup>8</sup> Whether this advantage was because of mitogenic effects of the growth factors in the aPRP or if the fibrin gel around the graft promoted, a more secure placement in the recipient site is unknown. Li et al have shown that aPRP promotes differentiation of stem cells to follicular cells through the upregulation of  $\alpha$ -catenin, induces proliferation in vitro of dermal papilla cells, and increases dermal papilla cell growth by activating ERK signaling. aPRP also prolonged anagen through increased expression of FGF-7 and increased cell survival by inhibiting apoptosis (associated with increased Bcl-2 protein levels as well as activated Akt signaling). Furthermore, aPRP injected every 3rd day for 3 weeks subcutaneously in mice improved hair regrowth.<sup>11</sup> Zimmer et al seeded neonatal dermal fibroblasts onto microbeads and cultured them under hypoxic conditions. The resultant media contained elevated levels of Wnt 7a (essential in stimulating the canonical Wnt pathway to cause stem cell differentiation into transient amplifying cells), VEGF, FGF, KGF, and follistatin (antagonistic to BMP in maintaining quiescent stem cells). In a 1-year study of patients treated with a single injection of 0.1 mL of this proprietary produced media, there was a 30% increase in terminal hair density, a 16% increase in hair count, and an 18% increase in thickness density. Addition of serum or prestimulation with either microdermabrasion, ablative/nonablative erbium-YAG laser treatment, or low level light therapy did not enhance results further. The effects of this treatment appeared to be quite localized, spreading less than 2 mm from the injection site.<sup>7</sup>

PRFM, first described in the literature as useful in treating deep nasolabial folds,<sup>22</sup> contains unactivated platelets associated with a fibrin matrix, and is not known to contain stem cells. It is theorized that this milieu accounts for the prolonged and more physiological release of growth factors (including VEGF, PDGF, EGF, and insulin-like growth factor) than traditional PRP, and release of significant levels of PDGF and VEGF has been shown to last for up to 7 days.<sup>23</sup> Fibrin presents binding sites for both platelets and growth factors; in soft tissue, this matrix may provide a scaffolding for soft tissue growth. Prior work has demonstrated the proangio-

genic effect of PRFM in the dermis, where a single intradermal injection was shown to stimulate collagen, capillary, and adipocyte development in the dermis.<sup>24</sup>

This study demonstrates a positive effect of intradermally injected PRFM on androgenetic alopecia. Cohen published a validating study of the HDI.<sup>12</sup> We chose to assess the HDI, as this measure takes into account both hair follicle density as well as hair shaft thickness, as both of these features affect the appearance of the hair. This is also a weakness of this study, as it is unclear if the positive effect seen after PRFM treatment is related to increased hair shaft thickness, increased numbers of growing hair follicles, or both.

Improvements in HDI were not seen immediately. At an average rate of hair growth of 1.25 cm/month, hair at the skin level at the periphery of the test area would be testable 1 month after treatment. Positive effects were not noted until 2 and 3 months after initial treatment (at the time of or 1 month after the third treatment). While the results at 6 months after initial treatment (3 months after the third treatment) were higher than pretreatment values, the 6-month value only approaches statistical significance. The significant attrition rate in this study limits the conclusions which can be drawn from our results; more patients are required to verify if this trend is indeed statistically significant. In addition, the wide variability of responses of patients to PRFM treatment (no improvement to significant improvement) mirrors the experience of Uebel et al with PRP.<sup>8</sup>

Not all subjects benefited from this treatment. Norwood classification and age were not predictive of success. However, subjects with an increase of at least 25% 1 month after initial treatment were more likely to have at least a 25% improvement 6 months after initial treatment (100 vs. 16.7%,  $p = 0.0476$ , chi-square analysis).

## Conclusion

PRFM increases the HDI significant 1 month after two or three intradermal scalp injections, and approaches statistical significance at 6 months with three injections. Most subjects described mild-moderate pain during treatment, but all subjects completed all planned treatments. Adverse effects were limited and treatment was tolerated by all subjects. PRFM may be a valuable tool in the treatment of androgenetic alopecia.

## References

- 1 Semalty M, Semalty A, Joshi GP, Rawat MSM. Hair growth and rejuvenation: an overview. *J Dermatolog Treat* 2011;22(3):123-132
- 2 Mecklenburg L, Tobin DJ, Müller-Röver S, et al. Active hair growth (anagen) is associated with angiogenesis. *J Invest Dermatol* 2000; 114(5):909-916
- 3 Kozłowska U, Blume-Peytavi U, Kodelja V, et al. Expression of vascular endothelial growth factor (VEGF) in various compartments of the human hair follicle. *Arch Dermatol Res* 1998;290(12): 661-668
- 4 Han JH, Kwon OS, Chung JH, Cho KH, Eun HC, Kim KH. Effect of minoxidil on proliferation and apoptosis in dermal papilla cells of human hair follicle. *J Dermatol Sci* 2004;34(2):91-98

- 5 Tosti A, Piraccini BM. Finasteride and the hair cycle. *J Am Acad Dermatol* 2000;42(5 Pt 1):848-849
- 6 Kang J-S, Zheng Z, Choi MJ, Lee SH, Kim DY, Cho SB. The effect of CD34+ cell-containing autologous platelet-rich plasma injection on pattern hair loss: a preliminary study. *J Eur Acad Dermatol Venereol* 2014;28(1):72-79
- 7 Zimmer MP, Ziering C, Zeigler F, et al. Hair regrowth following a Wnt- and follistatin containing treatment: safety and efficacy in a first-in-man phase 1 clinical trial. *J Drugs Dermatol* 2011;10(11):1308-1312
- 8 Uebel CO, da Silva JB, Cantarelli D, Martins P. The role of platelet plasma growth factors in male pattern baldness surgery. *Plast Reconstr Surg* 2006;118(6):1458-1466, discussion 1467
- 9 Rastegar H, Ahmadi Ashtiani H, Aghaei M, Ehsani A, Barikbin B. Combination of herbal extracts and platelet rich plasma induced dermal papilla cell proliferation: involvement of ERK and Akt pathways. *J Cosmet Dermatol* 2013;12(2):116-122
- 10 Takikawa M, Nakamura S, Nakamura S, et al. Enhanced effect of platelet-rich plasma containing a new carrier on hair growth. *Dermatol Surg* 2011;37(12):1721-1729
- 11 Li ZJ, Choi H-I, Choi D-K, et al. Autologous platelet-rich plasma: a potential therapeutic tool for promoting hair growth. *Dermatol Surg* 2012;38(7 Pt 1):1040-1046
- 12 Cohen B. The cross-section trichometer: a new device for measuring hair quantity, hair loss and hair growth. *Dermatol Surg* 2008;34(7):900-910
- 13 Jimenez F, Rulfemández JM. Distribution of human hair in follicular units. A mathematical model for estimating the donor size in follicular unit transplantation. *Dermatol Surg* 1999;25(4):294-298
- 14 International Society of Hair Restoration Surgery. International Society of Hair Restoration Surgery: 2011 Practice Census Results. Available at: [http://www.ishrs.org/sites/default/files/users/user3/FinalPracticeCensusReport7\\_11\\_11.pdf](http://www.ishrs.org/sites/default/files/users/user3/FinalPracticeCensusReport7_11_11.pdf). Accessed October 27, 2013
- 15 Garza LA, Liu Y, Yang Z, et al. Prostaglandin D2 inhibits hair growth and is elevated in bald scalp of men with androgenetic alopecia. *Sci Transl Med* 2012;4(126):26ra34
- 16 Sun T-T, Cotsarelis G, Lavker RM. Hair follicular stem cells: the bulge-activation hypothesis. *J Invest Dermatol* 1991;96(5):775-785
- 17 Lavker RM, Miller S, Wilson C, et al. Hair follicle stem cells: their location, role in hair cycle, and involvement in skin tumor formation. *J Invest Dermatol* 1993;101(1, Suppl):165-265
- 18 Yang CC, Cotsarelis G. Review of hair follicle dermal cells. *J Dermatol Sci* 2010;57(1):2-11
- 19 Cotsarelis G. Epithelial stem cells: a folliculocentric view. *J Invest Dermatol* 2006;126(7):1459-1468
- 20 Akiyama M, Smith LT, Holbrook KA. Growth factor and growth factor receptor localization in the hair follicle bulge and associated tissue in human fetus. *J Invest Dermatol* 1996;106(3):391-396
- 21 Festa E, Fretz J, Berry R, et al. Adipocyte lineage cells contribute to the skin stem cell niche to drive hair cycling. *Cell* 2011;146(5):761-771
- 22 Sclafani AP. Platelet-rich fibrin matrix for improvement of deep nasolabial folds. *J Cosmet Dermatol* 2010;9(1):66-71
- 23 Roy S, Driggs J, Elgharably H, et al. Platelet-rich fibrin matrix improves wound angiogenesis via inducing endothelial cell proliferation. *Wound Repair Regen* 2011;19(6):753-766
- 24 Sclafani AP, McCormick SA. Induction of dermal collagenesis, angiogenesis, and adipogenesis in human skin by injection of platelet-rich fibrin matrix. *Arch Facial Plast Surg* 2012;14(2):132-136